


PATIENT

Sasha Dimarcantonio

PRESENTING CLINICAL SIGNS

 History: Underweight. Specialist consulted suggested possible occult heart issue.
 -Abnormal PE/Chem/CBC/UA Results: NSF.

SPECIES

Feline

ECHOCARDIOGRAM FINDINGS

2D, m-mode, color flow and doppler imaging is available. The left ventricular wall is normal in dimension. There is a diffusely hyperechoic endocardium consistent with mild fibrosis. The papillary muscles are normal in size and hyperechoic. The endocardium appears normal. The left atrium is normal in size. The right atrium is normal in size. The right ventricle appears normal. The mitral valve is normal in structure and mobility. Normal flow through both the RVOT and LVOT. No obvious TR, AI or PI. No pleural or pericardial effusion seen. No obvious cardiac tumors.

BREED

DMH

SEX

Female Spayed

CARDIAC CHART
AGE

2 years

WEIGHT

13lbs

INTERPRETED BY

 Maggie Machen Lamy,
 DVM DACVIM
 (Cardiology)

IMAGING PERFORMED BY

Kelly Reschny, RVT

HOSPITAL NAME

 Maples Animal
 Hospital

REFERRING VET

Dr. Kazienko

INVOICE

22732

DATE

2/22/22

FELINE CARDIAC PARAMETERS	BODY WEIGHT (kg)	HR (BPM)	IVSd (cm) <small>(Moise, Pipers)</small>	LVIDd (cm) <small>(Moise, Pipers)</small>	LVWd (cm) <small>(Moise, Pipers)</small>	FS (%)	EF (%)
NORMAL PARAMETER	-----	150-240	0.35-0.55	<2 (mean 1.5)	3.5-0.55	35-67	80-100
PATIENT	5.9	196	0.43	1.1	0.46	50	86
FELINE CARDIAC PARAMETERS	LA/AO <small>(Boon)</small>	LA/AO HEART BASE (Swe) <small>(Abbott)</small>	LA 2D short axis Base view (cm) <small>(Abbott)</small>		LVOT VEL <small>(m/s)</small>	RVOT VEL <small>(m/s)</small>	E max <small>(m/s)</small>
NORMAL	<1.5	<1.3	<1.2		<1.6	<1.3	<0.9
PATIENT	1.3	1.2	0.9		0.7	0.9	NM

**Note: All measurements based upon multi-modal images and methods. An average value is reported.
 Adapted from June Boon, Veterinary Echocardiography, 1998
 Abbott J & MacLean H JVIM 2006;20: 111-119, Moise et al. Am J Vet Res 47:1476, 1986. Pipers et al. Am J Vet Res 40:882, 1979.*

INTERPRETATION OF THE FINDINGS & FURTHER RECOMMENDATIONS

Overtly normal cardiac structure and function. The LV wall thickness is normal and there is no evidence of elevated left atrial pressure. No obvious congenital issues are documented. These findings would suggest noncardiac cause of weight loss is

Given these findings, no medications are indicated. It is important to note that phenotypic HCM can develop at any phase of life in cats, and often does not accompany a heart murmur or PE abnormalities. Periodic screening is ideally recommended in all cats.

No cardiac contraindication for general anesthesia at this time.

Recommend recheck echocardiogram in 1 year to assess for development of disease, sooner if a murmur/gallop or clinical signs develop in the interim.



PATIENT

Sasha Dimarcantonio

SPECIES

Feline

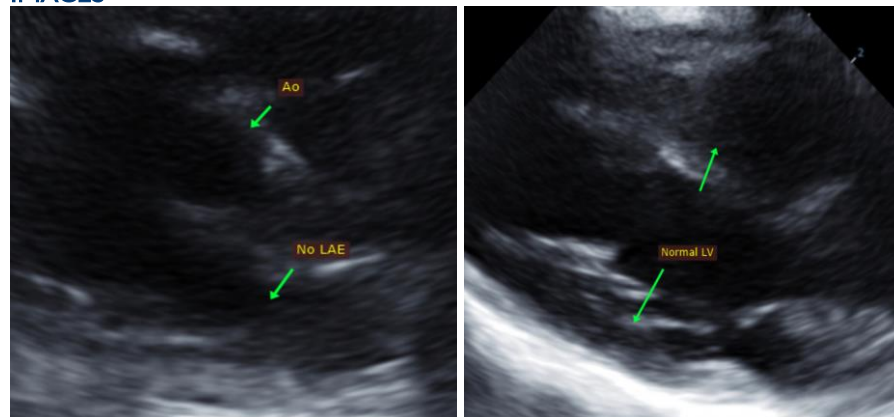
BREED

DMH

SEX

Female Spayed

IMAGES



AGE

2 years

The information and recommendations provided are based on the images presented by the referring veterinarian. No evaluation can be communicated regarding pathology that was not visible in the image/video clips provided.

WEIGHT

13lbs

Thank you for this referral. This report was generated using transcription software, and minor dictation errors may be present. If the clinical or image interpretation does not parallel your findings or if I can be of any further assistance, please contact me.

INTERPRETED BY

Maggie Machen Lamy,
DVM DACVIM
(Cardiology)

Maggie Machen Lamy, DVM
Diplomate of the American College of Veterinary Internal Medicine (Cardiology)
info@sonopath.com

**IMAGING
PERFORMED BY**

Kelly Reschny, RVT

HOSPITAL NAME

Maples Animal
Hospital

REFERRING VET

Dr. Kazienko

INVOICE

22732

DATE

2/22/22